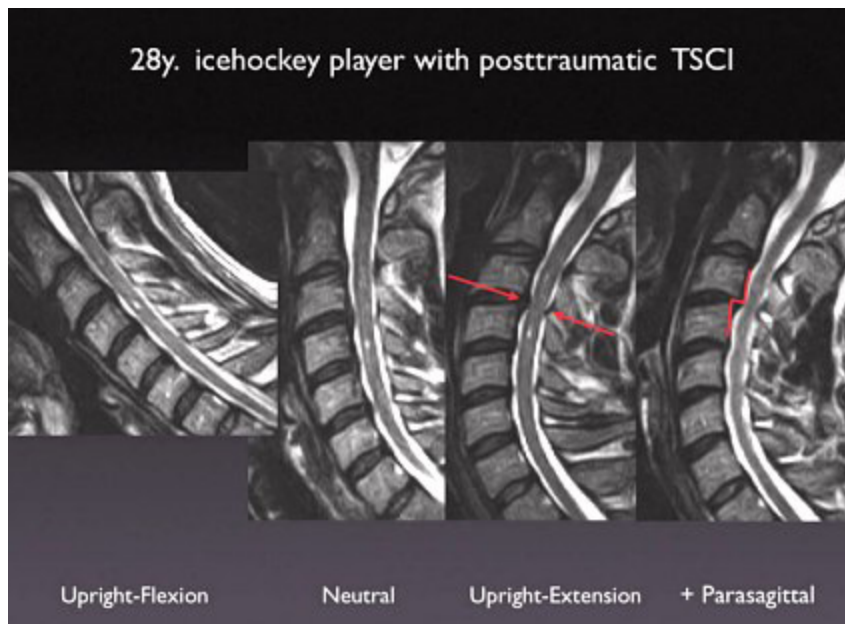


# Ice Hockey Player with Posttraumatic Transient Spinal Cord Injury (TSCI)

## Clinical Case Overview

Following a violent body check, a professional ice hockey player experienced a sudden total quadraparesis that paralyzed him during play for a full minute. The upright flexion and extension images showed two centromedullary cord contusions where only one was visible on the neutral upright scan. The two contusions accounted for the quadraparesis that caused his sudden transient paralysis on the ice while playing.



The critically compromising stenosis at C 3-4, visualized only by means of the FONAR Upright™ MRI extension images in this athlete with a congenitally tight spinal canal, was responsible for the acute cord compression and centromedullary contusions that resulted in the acute transient paralysis (1 minute duration) of this athlete. His lesions were visible only on upright extension.

Following anterior decompression and interbody fusion with a composite cage, this hockey player, who might otherwise have had his professional athletic career terminated, was back on the ice competing, 3 months after surgery.



J.P. Elsig, M.D.  
Fellow of the Swiss Orthopedic Society  
Member of the Board of the Swiss Spine Society  
FMRI Zentrum • Zurich, Switzerland